

Management of adrenal incidentalomas

KEVIN MURTAGH, NANA MUHAMMAD AND MAREK MILLER

The return of a scan result with reference to an incidental finding of an adrenal mass is a common scenario.¹ The scan was performed for another indication and the clinician is now faced with an unexpected problem. Here, we present some background to the problem, an overview of adrenal disease, and a suggested approach to the 'adrenal incidentaloma'.

The adrenals are paired glands of the endocrine system. Located in the retroperitoneum within Gerota's fascia, they lie above the superior pole of each kidney and have a characteristic yellow ochre colour, distinguishing them from the surrounding perinephric fat. Each gland typically weighs around 5g. The right gland is more pyramidal in shape, while the left is crescentic.

There are two discrete layers within each gland with different embryological origins. The outer cortex is of mesodermal derivation, and is responsible for steroid adrenocortical hormone production with its three zones – the zona glomerulosa, zona fasciculata and zona reticularis, producing mineralocorticoids (eg aldosterone), glucocorticoids (eg cortisol) and sex steroid hormones (eg androstenedione) respectively. The inner adrenal medulla is derived from the neural crest, secretes neuroactive catecholamines (eg adrenaline), and is innervated directly by presynaptic sympathetic fibres.

ADRENAL DISEASE

Adrenal pathology can be classified into disorders of the adrenal cortex, adrenal medulla or metastatic disease.

Disorders of the adrenal cortex

Excess cortisol

The overproduction of cortisol by the adrenal cortex can be a primary adrenal disorder or secondary to pituitary overproduction of ACTH. Autonomous glucocorticoid hypersecretion (AGH) by the adrenals is termed Cushing's syndrome if the well described clinical features are present. In the absence of clinical features, the term subclinical AGH or subclinical Cushing's syndrome is used. Both benign adenomas and malignant adenocarcinomas of the adrenal cortex can secrete excess cortisol, potentially resulting in the typical features of Cushing's.

Hyperaldosteronism

An excessive production of mineralocorticoids by the adrenals can result in hypertension, hypokalaemia, alkalosis, polyuria, fatigue and muscle cramping. If the excess production of aldosterone is due to an adenoma of the zona glomerulosa, then it is termed Conn's syndrome.

Addison's disease

Adrenal failure or primary insufficiency of the adrenal cortex is characterised by deficient secretion of glucocorticoids and

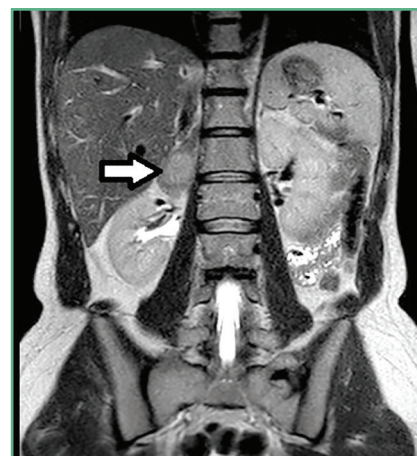

Figure 1. An MRI of a benign right-sided adrenal mass

Kevin Murtagh, Urology Specialist Registrar; Nana Muhammad, Core Trainee in Urology; Marek Miller, Consultant Urologist, Northampton General Hospital

mineralocorticoids. A rare entity, it is most commonly associated with autoimmune adrenalitis in Western populations. In the developing world, tuberculosis and other infective agents are the leading causes. Bilateral infiltration in diseases such as amyloidosis, and in bilateral metastatic infiltration of the cortices, can result in adrenal insufficiency, but these are rare. Bilateral and bulky disease (>4cm) is necessary to produce insufficiency. Addison described bilateral metastatic infiltration in his original series in 1855.²

Disorders of the adrenal medulla

Phaeochromocytoma

These are rare tumours of the catecholamine-producing cells of the adrenal medulla. They are typically benign, although 10% are malignant. The excess production of the catecholamines adrenaline and noradrenaline typically manifests as the triad of headache, paroxysmal sweating and tachycardia (Box 1).⁴ Phaeochromocytomas can be sporadic, but can be associated with genetic disorders (Box 2).³

Metastatic disease

While bilateral metastatic infiltration of the adrenals resulting in Addison's disease is a rare entity, metastases to the adrenals is common and should be considered in patients with a prior history of malignancy and an adrenal lesion (Box 3).

Box 1. Clinical manifestations of phaeochromocytomas⁴

- Headache
- Hypertension
- Palpitations
- Sweating
- Weight loss
- Pallor
- Nausea
- Anxiety

Box 2. Hereditary conditions associated with phaeochromocytomas³

- Multiple endocrine neoplasia (MEN2)
- Von Hippel-Lindau (VHL)
- Neurofibromatosis (NF1)
- Familial paraganglioma syndrome

Case study: an indeterminate lesion

A 68-year-old obese male patient with a history of hypertension, diabetes and peripheral vascular disease was referred to urology following a CT angiogram, which found an incidental adrenal lesion measuring 4cm. He reported no abdominal pain. Clinically, there was no evidence of skin changes, hirsutism or muscle weakness. Endocrine evaluation was unremarkable. CT showed an ill-defined border to the lesion, with no evidence of contrast washout, and Hounsfield units of 15. The case was discussed at a multidisciplinary team meeting, with previous imaging reviewed that did not show the lesion two years previously. Surgical excision was advised due to the indeterminate nature of the lesion. Surgery was performed by laparoscopic adrenalectomy without complication. Histology returned as an adrenocortical carcinoma.

APPROACH TO THE INCIDENTALOMA

The National Institute of Health recommends metabolic work-up of all incidentalomas.⁵ Studies have suggested that 11% are metabolically active and a further 7% are malignant (Box 4).⁶ This reinforces the fact that 'incidental' should not be synonymous with 'insignificant'. The characterisation of an adrenal lesion typically involves imaging, biochemical assessment of functionality and biopsy (in special cases).

Imaging

By their nature, incidentalomas often appear on imaging studies not optimised for assessing the adrenal glands. In such cases, re-imaging can be useful. The cornerstone for adrenal characterisation is cross-sectional imaging in the form of CT or MRI scanning (Figure 1). The most accessible and probably single best imaging modality is non-contrast CT scanning, which allows for assessment of size and contour, as well as density.⁷

Density

Adrenal lesions with low density (<10 Hounsfield units [HU] on CT scanning) are strongly suggestive of benign adenomas. Approximately 30% of benign adenomas have a density >10HU and can be difficult to distinguish from malignant lesions. Such benign lesions can be identified with contrast CT scanning, as they lose their

contrast enhancement at 10–15 minutes. This is the so-called 'washout effect', which has a sensitivity and specificity of near 100% in identifying benign adenomas.⁸

Size

There is a relationship between the size of a lesion and its malignant potential.⁹ Lesions <4cm have a low malignant potential (2% carcinomas). Lesions >6cm are best considered malignant and treated as such. Those lesions in the intermediate range of 4–6cm are unlikely to be malignant (6% carcinoma), although the consensus would suggest that these should be resected in otherwise healthy individuals.^{10,11}

Contour

Heterogenous, irregular and vascular lesions should be treated as malignant.⁶

Box 3. Primaries that can metastasise to the adrenals

- Renal cell carcinoma
- Cholangiocarcinoma
- Breast
- Seminoma
- Medullary thyroid
- Thymoma
- Cervix
- Chronic myeloid leukaemia
- Pancreas
- Transitional cell carcinoma

Box 4. Characteristics of incidental adrenal masses⁶

- **Metabolically active (11.2%)**
 - Cortisol-producing adenoma (5.2%)
 - Pheochromocytoma (5.1%)
 - Aldosterone-producing adenoma (0.9%)
- **Malignant (7.2%)**
 - Adrenocortical carcinoma (4.7%)
 - Metastasis (2.5%)

Biochemical assessment

All incidentally found adrenal lesions should be assessed for their functional status, as 11% will be metabolically active. Good practice is to test for cortisol and catecholamine hypersecretion in all patients, with added assessment of aldosterone levels in those with elevated blood pressure.¹⁰

Cortisol

There are three tests that can be used to assess for cortisol hypersecretion:

- Overnight dexamethasone suppression test
- Late-night salivary cortisol testing
- 24-hour urinary free cortisol.

The overnight dexamethasone suppression test involves administration of 1mg of dexamethasone at 11pm, with assessment of cortisol levels at 8am the following morning. A normal physiological response will result in suppression of cortisol levels.

Late-night salivary cortisol testing exploits the lack of normal diurnal cortisol fluctuations in hypersecreting patients. A saliva sample is taken at the patient's bedtime and tested for excessive cortisol levels. Shift workers and those with depression or chronic illness can have a false positive result. Patients should not smoke on the day of the test.

24-hour urinary free cortisol gives a direct reading of the free, bioavailable cortisol.

The choice of which of the above tests is used will depend on local practices.

Catecholamine testing

There are two principal tests used to assess for catecholamine excess:

- Free fractionated plasma metanephrines
- Urinary fractionated metanephrines.

Other tests are available, such as serum catecholamine levels and urinary vanillylmandelic acid (VMA) levels; however, these have a lower sensitivity and specificity, and have fallen out of favour. It is recommended that patients should undergo either a urine or a plasma test for metanephrine levels. The choice of test often depends on practicalities such as local availability and patient/doctor choice. There is little to suggest superiority of either test.¹²

Aldosterone levels

Hypertensive patients with an adrenal mass should undergo assessment for Conn's syndrome. The accepted test is a plasma aldosterone-to-renin ratio (ARR). An ARR of 20 with an aldosterone level above 15ng/ml is diagnostic of Conn's. Use of low potassium levels as a screen for hyperaldosteronism is unreliable, as less than 40% of patients that overproduce aldosterone will have hypokalaemia.¹³

Adrenal biopsy

In certain instances, adrenal biopsy can be undertaken. It is not commonly

performed due to advances in diagnostic imaging techniques, difficulty in distinguishing carcinomas from adenomas histologically, and the inherent risks of biopsy – not least haemorrhage. It would seem the role of biopsy lies in differentiating metastatic disease from native adrenal disease in those patients with known primaries. This is the cohort of patients whose cancer treatment may be altered should metastatic disease be found.¹⁴ It is imperative to assess for pheochromocytoma prior to biopsy, as hypertensive crises have been reported following biopsy.¹⁵

MANAGEMENT

Lesions with benign characteristics that are metabolically silent can be managed conservatively (Figure 2). A small proportion of such lesions can subsequently develop metabolic activity (approximately 2%).¹⁶ This is the rationale behind annual functional biochemical surveillance, in order to identify those in whom continued conservative management is inappropriate. There is a role for re-imaging lesions as an increase in size has been associated with malignant potential. There is no great consensus on follow-up, but annual review with re-imaging and biochemical assay for three to four years has been suggested.^{11,16}

Case study: annual surveillance

A 60-year-old patient, with a background of hypertension and no history of malignancy, was referred to the One-Stop Haematuria Clinic following an episode of visible haematuria. Flexible cystoscopy was normal. No cause for the haematuria was found. Incidentally, an ultrasound KUB showed a left adrenal mass measuring 2.5cm. There were no clinical features of Cushing's syndrome. Biochemical hormonal assessment (cortisol, catecholamines and aldosterone) did not suggest a functioning adenoma. A CT was performed, which showed homogenous contour to the lesion, with low density and 'washout effect' suggestive of a benign lesion. This was monitored with annual biochemical surveillance and repeat imaging at 6 and 12 months, which showed no evidence of mass enlargement.

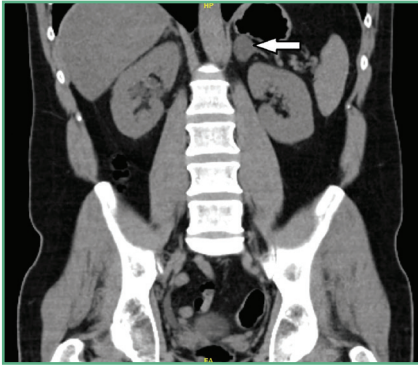


Figure 2. A benign adrenal adenoma

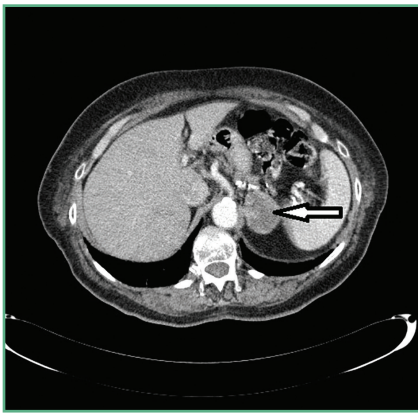


Figure 3. An axial slice of a contrast-enhanced CT scan of an adrenal carcinoma

Incidentalomas that have characteristics suggestive of malignancy or that are metabolically active should be considered for surgical removal and referral to an appropriate urologist, general or endocrine surgeon (Figure 3). Figure 4 shows a suggested management algorithm.

CONCLUSION

With the advances in modern imaging technology and their increased use, incidentally found adrenal lesions are common. All such findings warrant evaluation of their significance with regards to the likelihood of malignancy and their biochemical functional status. Surveillance is appropriate in non-functioning, benign-appearing incidentalomas. Surgical excision should be considered in all others.

Declaration of interests: none declared.

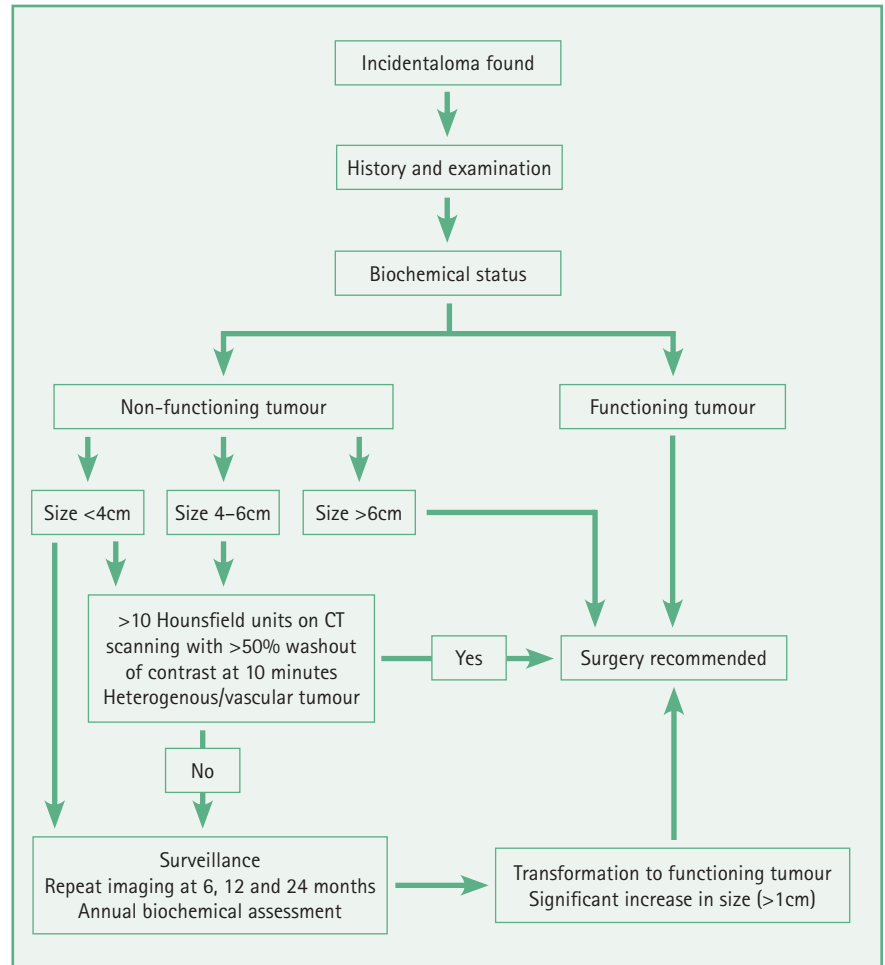


Figure 4. Management algorithm for adrenal incidentaloma

REFERENCES

1. Aron DC. The adrenal incidentaloma: disease of modern technology and public health problem. *Rev Endocr Metabol Disord* 2001;2:335-42.
2. Addison T. *On the constitutional and local effects of disease of the suprarenal capsules*. London: Samuel Highley, 1855.
3. Bravo EL, Tagle R. Pheochromocytoma: state-of-the-art and future prospects. *Endo Rev* 2003;24:539-53.
4. Lenders JW, Eisenhofer G, Mannelli M, Pacak K. Pheochromocytoma. *Lancet* 2005;36:665-75.
5. NIH state-of-the-science statement on management of the clinically inapparent adrenal mass ("incidentaloma"). *NIH Consens State Sci Statements* 2002;19:1-25.
6. Young WF. The incidentally discovered adrenal mass. *N Engl J Med* 2007;356: 601-10.
7. Korobkin M, Giordano TJ, Brodeur FJ. Adrenal adenomas: relationship between histologic lipid and CT and MR findings. *Radiology* 1996;200: 743-7.
8. Boland GW, Blake MA, Hahn PF, Mayo-Smith WW. Incidental adrenal lesions: principles, techniques, and algorithms for imaging characterization. *Radiology* 2008;249:756-75.
9. Angeli A, Osella G, Ali A, Terzolo M. Adrenal incidentaloma: an overview of clinical and epidemiological data from the National Italian Study Group. *Horm Res* 1997;47:279-83.

KEY POINTS

- **Incidental does not mean insignificant**
- **All patients with an adrenal incidentaloma need biochemical evaluation of functionality, as 11% are metabolically active**
- **7% of incidentalomas are malignant**
- **Radiological features used as a guide to management include density, size and contour – non-contrast CT scanning is the imaging modality of choice, with contrast 'washout' studies reserved for characterisation of those higher-density incidentalomas**
- **Surveillance of metabolically silent, benign-appearing lesions is favoured, although there is no consensus on duration of follow-up**
- **Where appropriate, surgical excision is the preferred treatment of malignant or functioning incidentalomas**

10. Grumbach MM, Biller BM, Braunstein GD, *et al.* Management of the clinically inapparent adrenal mass ("incidentaloma"). *Ann Intern Med* 2003;138:424–9.

11. Barry MK, van Heerden JA, Farley DR, *et al.* Can adrenal incidentalomas be safely observed? *World J Surg* 1998;22: 599–603.

12. Pacak K, Eisenhofer G, Ahlman H, *et al.* Pheochromocytoma: recommendations for clinical practice from the First International Symposium. October 2005. *Nat Clin Pract Endocrinol Metab* 2007;3:92–102.
13. Mulatero P, Stowasser M, Loh KC, *et al.* Increased diagnosis of primary aldosteronism, including surgically correctable forms, in centers from five continents. *J Clin Endocrinol Metab* 2004;89:1045–50.
14. Quayle FJ, Spittler JA, Pierce RA. Needle biopsy of incidentally discovered adrenal masses is rarely informative and potentially hazardous. *Surgery* 2007;142:497–502.
15. Mazzaglia PJ, Monchik JM. Limited value of adrenal biopsy in the evaluation of adrenal neoplasm: a decade of experience. *Arch Surg* 2009;144:465–70.
16. Barzon L, Sonino N, Fallo F. Prevalence and natural history of adrenal incidentalomas. *Eur J Endocrinol* 2003;149:273–85.